

Otolaryngology manifestations of COVID-19: a contemporary viewpoint

Since the first documented case of pneumonia of unknown origin hailed from Wuhan city, Hubei province, China, back in December 2019, the novel SARS-CoV-2 leading to COVID-19 has swept across the globe afflicted the people in every corner. As of 21 March 2021, the total case number has culminated to over 122 million worldwide, with a mortality rate of 2.2%.¹ 11 March 2021 marks the first anniversary since WHO declared the COVID-19 outbreak a pandemic. With the vaccine challenges that lie ahead, the light at the end of the tunnel remains elusive.

We learnt that the transmission routes are via respiratory droplet, aerosols and by contact that may be indirect, which succinctly impose a remarkably high risk to the head and neck surgeons who often deal with aerosol-generating procedures. In fact, the first doctor who succumbed to COVID-19 in Wuhan was an otolaryngologist.² The acknowledgement of a heterogeneous spectrum of clinical manifestations of SARS-CoV-2 viral infection, ranging from asymptomatic to severe disease with multiple organ failure, is of paramount importance. Apart from the overall presentation being fever, myalgia and lower respiratory tract symptoms of cough and dyspnoea, extrapulmonary symptomatology of COVID-19 manifested through a variety of ear, nose, throat (ENT) complaints have been gradually recognised.

In conjunction with hypogeusia, smell deficit constitutes the earliest reported ENT manifestation of the novel coronavirus. Olfactory dysfunction was identified in a substantial fraction of patients who suffered from COVID-19, with a prevalence of 47.85% worldwide.³ The idiosyncratic characteristics of smell disturbance attributed to COVID-19 include its sudden onset, transient duration, and in most cases, rapid recuperation. Additionally, smell deficit may manifest as a sole nasal symptom without concomitant rhinorrhea or congestion.⁴

Other sinonasal manifestations, namely nasal congestion and rhinorrhea, have been reported at a much lower occurrence rate. Paradoxically, a significantly lower amount of viral entry receptors, was observed in patients with allergic airway diseases, of which the diagnostic

symptoms include nasal discharge and/or blocked nose.⁵ The prevalence of chronic rhinosinusitis in patients with COVID-19 was comparable with the general population, implying that sinusitis may not increase viral infection susceptibility. The underlying chronic eosinophilic inflammation with long-term exposure to corticosteroid in allergic airway diseases was found to downregulate the viral entry gene expression, inferring the possibility of a protective role against COVID-19 infection.⁵



How about the otological presentation? The theory of virus-induced aural dysfunction has always been a familiar certitude in the field of medicine. Viruses can damage the inner ear structures by initiating a host-immune response. A diversity of overlapped manifestations, including hearing impairment, vertigo, peripheral facial palsy and tinnitus with various onset and severity, have been described. There is scattered but emerging evidence of COVID-19-related peripheral facial palsy. The correlation between the two, however, remains undetermined. Understandably, the SARS-CoV-2 possess neurotropic and neuroinvasive properties, ergo the predilection of a viral-induced pathogenesis of facial palsy includes direct infection injury, ischaemia of the vasa nervorum, and local inflammation giving rise to demyelination.⁶

The SARS-CoV-2 infection may manifest itself through inner ear complaints such as vertigo and hearing loss. Of note, dizziness was among the most typical neurological manifestation of COVID-19 disease.⁷ Akin to the sequelae of virus infection on the olfactory sense's neural pathway, the proposition of aural dysfunction due to vascular hypoperfusion and local inflammation on the audiovestibular centres caused by SARS-CoV-2 infection is plausible.⁸ The viruses may intrude on the haematological path by binding the erythrocytes via the β chain. The ensuing viral deposit onto the ACE2 receptor protein at the temporal lobe and hearing centre then trigger a cascade of a local inflammatory process, paving the way to hearing loss and imbalance.⁸ Intriguingly, the risk of hearing damage seems to be reciprocating the severity of COVID-19 infection, granted that the fact patient might also complain of hearing impairment as the sole symptom.⁹ It is crucial to establish the dichotomy between non-vertiginous dizziness and vertigo. While dizziness may be related to a myriad of causes, vertigo, on the other hand, is almost always caused by a vestibular pathology. Pertinent history,

including the characteristic of a false sense of motion, the duration and frequency, and most importantly, other associated otological complaints such as hearing loss and tinnitus, should be carefully evaluated. It is worthy of note that vertigo, although a non-specific COVID-19 symptom, should not be taken lightly for its detrimental repercussion.

SARS-CoV-2 has also been identified in the saliva due to the high expression of ACE2 in the salivary gland's lining epithelial cells. There have been anecdotal reports of orofacial manifestation link to COVID-19. Interestingly, such clinical features were reported to be the first clinical sign of SARS-CoV-2 infection.¹⁰ The archetypal presentation of a unilateral parotid swelling associated with pain and non-specific ulcerative or vesicubullous lesion of the oral mucosa indifferent from other inflammatory or infective cause then raised the concern of the virus as a potential great masquerader.

The battle against COVID-19 is not over. Early recognition of atypical manifestation of SARS-CoV-2 infection remains pivotal to avert misdiagnosis and delay in management. Therefore, we urge the treating physicians to be well informed of the growing spectrum of clinical presentation of COVID-19 while remaining vigilant for potentially disastrous consequences.

Geng Ju Tuang , **Adi Farhan Abdul Wahab**, **Salina Husain** 

Department of Otorhinolaryngology, Head and Neck Surgery, Hospital Universiti Kebangsaan Malaysia, Cheras, Kuala Lumpur, Malaysia

Correspondence to Dr Salina Husain, Department of Otorhinolaryngology, Head and Neck Surgery, Hospital Universiti Kebangsaan Malaysia, Cheras 56000, Malaysia; drsalina_h@yahoo.com

Contributors GJT was responsible in manuscript drafting, reviewing, editing and manuscript submission. AFAW was responsible in manuscript drafting, reviewing and editing. SH was responsible in supervising, manuscript reviewing and editing. All authors gave final approval for the version to be published.

Funding The authors have not declared a specific grant for this research from any funding agency in the public, commercial or not-for-profit sectors.

Competing interests None declared.

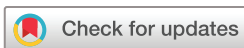Patient consent for publication Not required.

Provenance and peer review Not commissioned; internally peer reviewed.

This article is made freely available for use in accordance with BMJ's website terms and conditions for the duration of the covid-19 pandemic or until otherwise determined by BMJ. You may use, download and print the article for any lawful, non-commercial purpose (including text and data mining) provided

that all copyright notices and trade marks are retained.

© Author(s) (or their employer(s)) 2021. No commercial re-use. See rights and permissions. Published by BMJ.



To cite Tuang GJ, Abdul Wahab AF, Husain S. *Postgrad Med J* Epub ahead of print: [please include Day Month Year]. doi:10.1136/postgradmedj-2021-140169

Accepted 1 April 2021

Postgrad Med J 2021;0:1–2.
doi:10.1136/postgradmedj-2021-140169

ORCID iDs

Geng Ju Tuang <http://orcid.org/0000-0001-7803-5519>

Salina Husain <http://orcid.org/0000-0001-7683-2143>

REFERENCES

- 1 Who.int [internet]. World Health organization: weekly epidemiological update on COVID-19 – 21 March 2021. Available: <https://www.who.int/publications/m/item/weekly-epidemiological-update---23-march-2021> [Accessed 27 Mar 2021].
- 2 Kulcsar MA, Montenegro FL, Arap SS, *et al*. High risk of COVID-19 infection for head and neck surgeons. *Int Arch Otorhinolaryngol* 2020;24:e129–30.
- 3 Saniasiaya J, Islam MA, Abdullah B. Prevalence of olfactory dysfunction in coronavirus disease 2019 (COVID-19): a meta-analysis of 27,492 patients. *Laryngoscope* 2021;131:865–78.
- 4 Butowt R, von Bartheld CS. Anosmia in COVID-19: underlying mechanisms and assessment of an olfactory route to brain infection. *Neuroscientist* 2020;107385842095690.
- 5 Saheb Sharif-Askari F, Saheb Sharif-Askari N, Goel S, *et al*. Are patients with chronic rhinosinusitis with nasal polyps at a decreased risk of COVID-19 infection? *Int Forum Allergy Rhinol* 2020;10:1182–5.
- 6 Lima MA, Silva MTT, Soares CN, *et al*. Peripheral facial nerve palsy associated with COVID-19. *J Neurovirol* 2020;26:941–4.
- 7 Saniasiaya J, Kulasegarah J. Dizziness and COVID-19. *Ear Nose Throat J* 2021;100:29–30.
- 8 Saniasiaya J. Hearing loss in SARS-CoV-2: what do we know? *Ear Nose Throat J* 2021;100:152S–4.
- 9 Fraczek M, Resler K, Szetela B. Can we expect more patients with hearing loss due to COVID-19? *Hear J* 2020;73:8–10.
- 10 Halboub E, Al-Maweri SA, Alanazi RH, *et al*. Orofacial manifestations of COVID-19: a brief review of the published literature. *Braz Oral Res* 2020;34:e124.